

# Sagittal Spinal Pelvic Alignment

Eric Klineberg, MD<sup>a,\*</sup>, Frank Schwab, MD<sup>b</sup>,  
Justin S. Smith, MD, PhD<sup>c</sup>, Munish C. Gupta, MD<sup>a</sup>,  
Virginie Lafage, PhD<sup>b</sup>, Shay Bess, MD<sup>d</sup>

## KEYWORDS

• Spine • Deformity • Adult • Radiographic • Pelvic • Sagittal

## KEY POINTS

- The spine and pelvis have robust compensatory mechanisms to achieve a globally well-aligned spine (center of mass over pelvis, horizontal eye gaze) to allow for minimum energy expenditure.
- Pelvic incidence is a morphometric parameter and is both constant and dictates the amount of lumbar lordosis needed to achieve a globally aligned spine.
- Pelvic tilt and sacral slope are compensatory mechanisms that reflect pelvic rotation in space (sagittal) and reflect efforts to maintain global alignment in the setting of spinal deformity.
- Pelvic parameters play a critical role in health-related quality of life outcome measures and must be accounted for when planning spinal surgery.
- Underappreciation of the compensatory mechanisms in the pelvis may lead surgeons to poor surgical planning and corresponding poor clinical outcomes.

## INTRODUCTION

Adult spinal deformity is a broad category that encompasses a diverse group of spinal malalignment patterns. The range of diseases extends from simple biplanar deformity to a more complex three-dimensional deformity with significant loss of coronal and sagittal alignment. With an aging population, the prevalence of adult spinal deformity is increasing in the United States and may be approaching rates as high as 70% among elderly individuals.<sup>1</sup> Although most patients are able to tolerate mild to moderate deformities without significant dysfunction, there is a subset of patients who experience significant back pain,

root compression, and loss of acceptable standing global alignment.<sup>2</sup> Whereas historically, treatment focused on scoliosis correction and coronal plane deformity, more recent data have shown the impact of the sagittal plane, and lumbopelvic parameters on health-related quality of life (HRQoL).<sup>3–6</sup> These parameters are therefore critical to understand and integrate for successful surgical planning in the setting of adult spinal deformity.<sup>3,4,7,8</sup>

## CONE OF ECONOMY

The ability to maintain an upright posture and horizontal eye gaze is fundamental to normal activities

---

Grants, Technical Support, and Corporate Support: No funding was received in support of this study.  
IRB: NA (review article).

<sup>a</sup> Department of Orthopaedic Surgery, University of California – Davis, 4860 Y Street, Suite 3800, Sacramento, CA 95817, USA; <sup>b</sup> Department of Orthopaedic Surgery, NYU Hospital for Joint Diseases, 306 East 15th Street, Suite 1F, New York, NY 10003, USA; <sup>c</sup> Department of Neurosurgery, University of Virginia, PO Box 800212, Charlottesville, VA 22908, USA; <sup>d</sup> Rocky Mountain Hospital for Children, 2055 High Street, Suite 130, Denver, CO 80205, USA

\* Corresponding author. Department of Orthopaedic Surgery, University of California – Davis, 4860 Y Street, #3800, Sacramento, CA 95817.

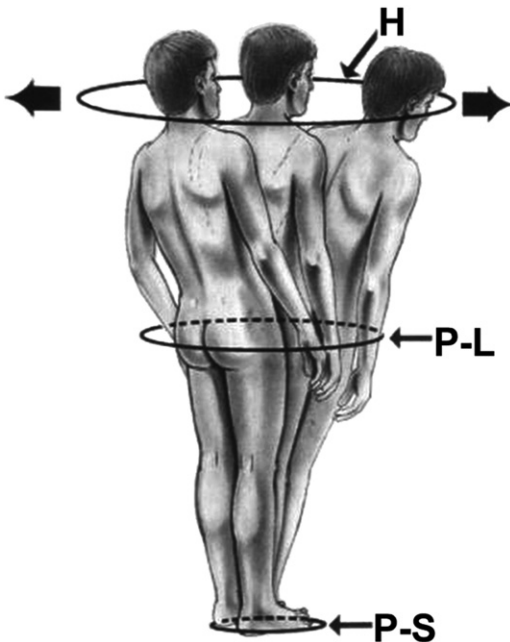
E-mail address: [eric.klineberg@ucdmc.ucdavis.edu](mailto:eric.klineberg@ucdmc.ucdavis.edu)

Neurosurg Clin N Am 24 (2013) 157–162

<http://dx.doi.org/10.1016/j.nec.2012.12.003>

1042-3680/13/\$ – see front matter © 2013 Elsevier Inc. All rights reserved.

of daily living. Spinal deformity creates suboptimal spinal alignment, and may result in increased energy requirements to maintain appropriate posture and balance. The spine is not the only structure that is involved in the standing axis, and any analysis that attempts to understand global alignment must involve the pelvis and lower extremities.<sup>9-15</sup> Dubousset<sup>16</sup> was the first surgeon to consider the pelvis as a critical structure in the setting of global alignment and introduced the concept of a cone of economy (Fig. 1). The cone is defined as originating from the feet and projected upwards to define the range of mobility that the body can achieve with a minimum of energy expenditure, without external support. If the spinal alignment is ideal, the patient is able to maintain an upright posture in the zone of economy and allow for painless upright posture at rest and during motion.<sup>9</sup> If the body is forced out of this cone (spinal deformity), the energy expenditure increases with the need for compensatory mechanisms (ie, bending of the knee, or pelvic retroversion). The patient may require assistive devices if internal compensation is insufficient

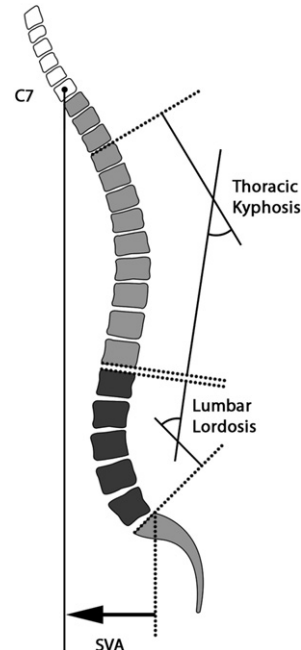


**Fig. 1.** Cone of economy defined as originating from the feet and projected upwards to define the range of mobility that the body can achieve with a minimum of energy expenditure, without external support. H, Head; P-L, Pelvic Level; and P-S, Polygon of Sustentation. (From Dubousset J. Three-dimensional analysis of the scoliotic deformity. In: Weinstein SL (ed): *The Pediatric Spine: Principles and Practice*. New York: Raven Press, 1994; with permission.)

or requires excessive energy.<sup>16</sup> The degree of global alignment can be determined by radiographic parameters that assess the patient in a static position. Such an approach allows the physician to determine where the trunk is in relation to the pelvis and to determine some of the compensatory mechanisms that are being used. For optimal radiographic analysis, it is essential that patients stand upright in a free-standing position<sup>17</sup> and then 91.44-cm (36-in) cassette films are obtained in both the coronal and sagittal planes.

## SAGITTAL VERTICAL AXIS

Global spinal alignment is most often assessed by determining the sagittal vertical axis (SVA). The SVA is determined by measuring the horizontal distance from the C7 plumb line and the posterior superior aspect of the S1 vertebral body (Fig. 2). Positive and negative values are defined depending whether the C7 plumb line falls anterior or posterior, respectively. Normative values have been established as being less than 5 cm. The C7 plumb serves as a surrogate for where the



**Fig. 2.** Sagittal spinal parameters. The SVA is determined by measuring the horizontal distance from the C7 plumb line and the posterior superior aspect of the S1 vertebral body. Lumbar lordosis is measured from the superior end plate of L1 to the superior end plate of S1. Thoracic kyphosis can be determined by measuring the angle of the thoracic spine from the superior vertebral end plate of T2 and the inferior end plate of T12.

head falls in space but ignores the cervical alignment. Similarly, the S1 vertebral body serves as a surrogate for where the feet are in space but ignores the contribution of the foot, knees, hips, and pelvis. Although this global assessment gives the surgeon a general idea of the global sagittal deformity, it underappreciates the role of the pelvis and compensatory mechanisms used.

## SPINAL ALIGNMENT

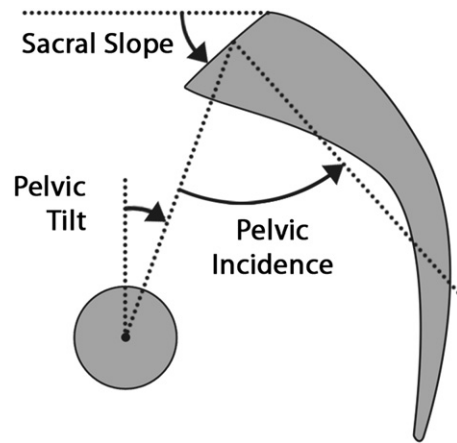
Global spinal alignment may be subdivided into its component parts, namely the thoracic kyphosis (TK) and lumbar lordosis (LL). LL is measured from the superior end plate of L1 to the superior end plate of S1 and plays an important role in maintenance of upright posture (see [Fig. 2](#)).<sup>14</sup> Normative values of 40° to 60° have been described in the adult population; however, that number seems to decrease with aging. Decreasing lordosis or flat-back deformity has been associated with inability to maintain spinal balance, and resultant pain and disability.<sup>18</sup> In addition, TK can be determined by measuring the angle of the thoracic spine from the superior vertebral end plate of T2 and the inferior end plate of T12. TK also increases with age and influences global spinal alignment.

## THE PELVIS

The pelvis is the base of the spine. Its morphology determines the foundation on to which the spine is seated. Although the morphology is relatively constant in adulthood, the mobile spine may adapt to the sacral position, adjusting the degree of curvature to achieve a mechanically efficient posture.<sup>19</sup> In order for the body to achieve an efficient upright posture, the spine must be in harmony with the pelvis. This harmony has been coined the spinopelvic alignment<sup>20</sup> to describe the synergistic relationship between pelvic morphology and spinal curvature. To understand the spinopelvic alignment, it is critical to understand the static morphometric pelvic parameters (pelvic incidence [PI]) and the dynamic parameters (sacral slope [SS], pelvic tilt [PT]), and how these interact with spinal regional curvatures (LL, TK).

### PI

PI is defined as the angle subtended by a line drawn between the center of the femoral heads and the sacral end plate and a line drawn perpendicular to the sacral end plate ([Fig. 3](#)).<sup>21</sup> This angle represents the sacral relationship to the acetabulum and assumes limited motion through the sacroiliac joints. PI normative values of 50 to 55 are typically found; however, the individual reported range



**Fig. 3.** Pelvic parameters. PI is described as an angle subtended by a line that is drawn from the center of the femoral heads to the midpoint of the sacral end plate and a line perpendicular to the center of the sacral end plate. PT is defined as the angle created by a line from the midpoint of the sacral end plate to the center femoral heads and a vertical plumb line. The sacral slope is the angle between the superior sacral end plate and a horizontal reference line.

may vary substantially from 28 to 84.<sup>6</sup> PI is therefore a static morphologic parameter that is consistent throughout a patient's life time, with only slight changes that occur during growth.<sup>22</sup> After this time, PI is a fixed parameter (minimal sacroiliac motion), which reliably reproduces the relationship of the sacrum to the pelvis.<sup>22</sup> The constant PI has a profound effect on the spinal parameters. With a large PI, the sacrum is more vertical and thus requires a larger LL to maintain proper global sagittal alignment of the trunk. Conversely, with a low PI, the more horizontal sacrum requires a smaller LL to achieve a balanced posture. Schwab and colleagues<sup>14</sup> reported on the role of PI in determining the degree of LL and developed a formula, based on the work of Boulay and colleagues,<sup>23</sup> in which ideal LL = PI + 9° (±9°).

### PT

PT is defined as the angle created by a line from the midpoint of the sacral end plate to the center femoral heads and a vertical plumb line (see [Fig. 3](#)).<sup>4</sup> This is a dynamic pelvic parameter, which can increase or decrease through rotation about the hip axis and can also change over time.<sup>4,14</sup> With age, the hip joints may become arthritic, and thereby lose range of motion, most notably the ability to recruit hip extension in the setting of spinal deformity. This situation may in turn limit the ability for a patient to augment pelvic retroversion (PT). In addition, as individuals age, the LL

may decrease because of disk settling, adding the need to increase PT to maintain global alignment. Increasing PT retroverts the pelvis and requires hip extension and has limitations. As the PT increases, it represents a compensatory mechanism that requires both effort and energy. Schwab and colleagues<sup>14</sup> found a significant correlation between HRQoL outcome measures and PT. With increasing PT, HRQoL deteriorates, and an ideal pelvis version (surgical goal) of PT of less than 20° has been established.<sup>6</sup> Normative values may range from -5° to 30°, with a mean of 11° to 15°. However; unlike PI, PT changes with aging and has been found to increase, because of lost lordosis and increasing TK, reflecting the recruitment of a compensatory mechanism.<sup>22</sup>

## SS

SS is defined as the angle created by a line drawn parallel to the end plate of the sacrum to a horizontal reference line (see [Fig. 3](#)).<sup>24</sup> By performing simple geometry, PI is defined as the sum of PT and SS ( $PI = PT + SS$ ).<sup>4,6,8,9,24</sup> According to the formula, as PT increases (pelvic retroversion), the SS decreases and the sacral end plate becomes more horizontal.<sup>14</sup>

## SPINOPELVIC ALIGNMENT

Historically, the focus of surgical treatment of scoliosis has been on the coronal alignment and less on the sagittal parameters. However, several studies<sup>3,6,25</sup> have shown that proper sagittal alignment is the single most important factor that determines the outcome for adults undergoing spinal deformity surgery. Patients with spinal deformity and undercorrected sagittal alignment with decreased LL have significantly worse HRQoL scores for physical and social function, self-image, and pain.<sup>3</sup> Several recent studies<sup>10,11,13,26,27</sup> have emphasized the relevance of LL and corresponding influence of pelvic parameters on the standing alignment in normal adults and children.

The pelvis exerts significant influence on the spine, and vice versa PI determines the optimal LL, and is different for each individual.<sup>13,22,24,28</sup> Boulay and colleagues<sup>23</sup> determined the optimal LL to achieve a harmonious balance and created a mathematical formula to predict the ideal LL for a given PI. Compensatory mechanisms can allow the pelvis to retrovert and increase the PT as the LL decreases, and in so doing, achieve a globally aligned trunk. However, this abnormal PT is often a marker of disability and underlying spinal malalignment and underscores the importance of the pelvis in determining overall alignment.<sup>12</sup>

## SURGICAL PLANNING

Understanding and measuring the global spinal parameters, as well as the regional specific parameters, allows the surgeon to plan more effectively when determining the amount of correction necessary to achieve a good outcome. A high PT indicates pelvic retroversion, which is caused by an attempt to compensate for decreased LL.<sup>14</sup> Correction of deformity requires correction of not only the LL but must do so in the context of understanding the impact on PT. Failure to recognize an elevated PT leads to a fixed deformity, with inadequate correction and persistent clinical symptoms of global sagittal malalignment.<sup>9</sup> The optimal surgical goal should be to return the PT to a more physiologically normal value of less than 20°. Proper version of the pelvis allows for more efficient standing and locomotion. Restoration of PT independently correlates with walking tolerance.<sup>4,14,29</sup>

Recently, a new classification system has been developed for adult deformity, the Scoliosis Research Society (SRS)-Schwab classification, which incorporates spinal and pelvic parameters with high interobserver and intraobserver reliability and is useful for classifying patients.<sup>30</sup> This classification system groups patients by their primary deformity and uses SVA, PT, and PI-LL mismatch as modifiers. Recent unpublished data from Smith and colleagues<sup>31</sup> evaluated 341 patients with adult deformity and assessed their improvement in spinopelvic parameters using the SRS-Schwab classification at 1 year. These investigators found significant correlation with improvement in PT or PI-LL modifiers with HRQoL outcomes. Schwab and colleagues<sup>5</sup> found that failure to achieve successful realignment occurred most in patients with large SVA, PT, PI, and greater mismatch. This finding suggests that even for experienced deformity surgeons, spinal realignment for sagittal plane deformity requires meticulous analysis and planning to customize treatment on a patient-specific level.

## SUMMARY

Many of the current sagittal plane radiographic parameters (SVA, TK, LL) do not account for compensatory mechanisms above and below the measured segments. Compensation may occur through the feet, knees, hips, pelvis, and cervical spine to restore horizontal eye gaze and maintain proper truncal posture. Excessive compensation leads to pain and disability. The pelvis plays a critical role in the maintenance of global spinal alignment. Restoration of spinopelvic harmony allows the

spine and pelvis to use minimal energy expenditure to maintain the patient within the ideal zone of the cone of economy. Matching the pelvic and spinal parameters allows the surgeon to achieve a properly aligned spine. Apparently normal SVA is insufficient in assessing global spinal alignment, because significant pelvic compensatory mechanisms can be in recruitment. The most relevant is the PT, which increases to compensate for regional malalignment in the lumbar or thoracic spine. Underappreciation of the dynamic pelvic parameters (PT, SS) leads to undercorrection of spinal deformity and poor patient outcomes.

## REFERENCES

- Schwab F, Dubey A, Pagala M, et al. Adult scoliosis: a health assessment analysis by SF-36. *Spine (Phila Pa 1976)* 2003;28(6):602–6.
- Smith JS, Fu KM, Urban P, et al. Neurological symptoms and deficits in adults with scoliosis who present to a surgical clinic: incidence and association with the choice of operative versus nonoperative management. *J Neurosurg Spine* 2008;9(4):326–31.
- Glassman SD, Bridwell K, Dimar JR, et al. The impact of positive sagittal balance in adult spinal deformity. *Spine (Phila Pa 1976)* 2005;30(18):2024–9.
- Lafage V, Schwab F, Patel A, et al. Pelvic tilt and truncal inclination: two key radiographic parameters in the setting of adults with spinal deformity. *Spine* 2009;34(17):E599–606.
- Schwab FJ, Patel A, Shaffrey CI, et al. Sagittal realignment failures following pedicle subtraction osteotomy surgery: are we doing enough?: Clinical article. *J Neurosurg Spine* 2012;16(6):539–46.
- Schwab F, Patel A, Ungar B, et al. Adult spinal deformity-postoperative standing imbalance: how much can you tolerate? An overview of key parameters in assessing alignment and planning corrective surgery. *Spine (Phila Pa 1976)* 2010;35(25):2224–31.
- Bridwell KH, Glassman S, Horton W, et al. Does treatment (nonoperative and operative) improve the two-year quality of life in patients with adult symptomatic lumbar scoliosis: a prospective multicenter evidence-based medicine study. *Spine* 2009;34(20):2171–8.
- Lafage V, Bharucha NJ, Schwab F, et al. Multicenter validation of a formula predicting postoperative spinopelvic alignment. *J Neurosurg Spine* 2012;16(1):15–21.
- Ames CP, Smith JS, Scheer JK, et al. Impact of spinopelvic alignment on decision making in deformity surgery in adults: a review. *J Neurosurg Spine* 2012;16(6):547–64.
- Labelle H, Roussouly P, Berthonnaud E, et al. The importance of spino-pelvic balance in L5-s1 developmental spondylolisthesis: a review of pertinent radiologic measurements. *Spine (Phila Pa 1976)* 2005;30(Suppl 6):S27–34.
- Legaye J, Duval-Beaupere G. Sagittal plane alignment of the spine and gravity: a radiological and clinical evaluation. *Acta Orthop Belg* 2005;71(2):213–20.
- Neal CJ, McClendon J, Halpin R, et al. Predicting ideal spinopelvic balance in adult spinal deformity. *J Neurosurg Spine* 2011;15(1):82–91.
- Roussouly P, Gollogly S, Berthonnaud E, et al. Classification of the normal variation in the sagittal alignment of the human lumbar spine and pelvis in the standing position. *Spine (Phila Pa 1976)* 2005;30(3):346–53.
- Schwab F, Lafage V, Patel A, et al. Sagittal plane considerations and the pelvis in the adult patient. *Spine* 2009;34(17):1828–33.
- Schwab F, Lafage V, Boyce R, et al. Gravity line analysis in adult volunteers: age-related correlation with spinal parameters, pelvic parameters, and foot position. *Spine* 2006;31(25):E959–67.
- Dubousset J. Three-dimensional analysis of the scoliotic deformity. In: Weinstein S, editor. *The pediatric spine: principles and practice*. New York: Raven Press; 1994. p. 479–96.
- Horton WC, Brown CW, Bridwell KH, et al. Is there an optimal patient stance for obtaining a lateral 36° radiograph? A critical comparison of three techniques. *Spine* 2005;30(4):427–33.
- Lu DC, Chou D. Flatback syndrome. *Neurosurg Clin N Am* 2007;18(2):289–94.
- Labelle H, Roussouly P, Berthonnaud E, et al. Spondylolisthesis, pelvic incidence, and spinopelvic balance: a correlation study. *Spine* 2004;29(18):2049–54.
- Vaz G, Roussouly P, Berthonnaud E, et al. Sagittal morphology and equilibrium of pelvis and spine. *Eur Spine J* 2002;11(1):80–7.
- Legaye J, Duval-Beaupere G, Hecquet J, et al. Pelvic incidence: a fundamental pelvic parameter for three-dimensional regulation of spinal sagittal curves. *Eur Spine J* 1998;7(2):99–103.
- Mac-Thiong JM, Berthonnaud E, Dimar JR 2nd, et al. Sagittal alignment of the spine and pelvis during growth. *Spine* 2004;29(15):1642–7.
- Boulay C, Tardieu C, Hecquet J, et al. Sagittal alignment of spine and pelvis regulated by pelvic incidence: standard values and prediction of lordosis. *Eur Spine J* 2006;15(4):415–22.
- Berthonnaud E, Dimnet J, Roussouly P, et al. Analysis of the sagittal balance of the spine and pelvis using shape and orientation parameters. *J Spinal Disord Tech* 2005;18(1):40–7.
- Glassman SD, Carreon L, Dimar JR. Outcome of lumbar arthrodesis in patients sixty-five years of age or older. Surgical technique. *J Bone Joint Surg Am* 2010;92(Suppl 1 Pt 1):77–84.
- Lowe T, Berven SH, Schwab FJ, et al. The SRS classification for adult spinal deformity: building on the

- King/Moe and Lenke classification systems. *Spine* 2006;31(Suppl 19):S119–25.
27. Benner B, Ehni G. Degenerative lumbar scoliosis. *Spine (Phila Pa 1976)* 1979;4(6):548–52.
  28. Mac-Thiong JM, Labelle H, Berthodnaud E, et al. Sagittal spinopelvic balance in normal children and adolescents. *Eur Spine J* 2007;16(2):227–34.
  29. Skalli W, Zeller RD, Miladi L, et al. Importance of pelvic compensation in posture and motion after posterior spinal fusion using CD instrumentation for idiopathic scoliosis. *Spine (Phila Pa 1976)* 2006;31(12):E359–66.
  30. Schwab F, Ungar B, Blondel B, et al. Scoliosis Research Society-Schwab adult spinal deformity classification: a validation study. *Spine (Phila Pa 1976)* 2012;37(12):1077–82.
  31. Scoliosis Research Society, Podium Presentation. Chicago, 2012.